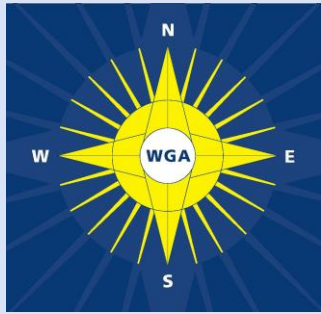

Kugler Publications, The Hague, The Netherlands

# Glaucoma Surgery

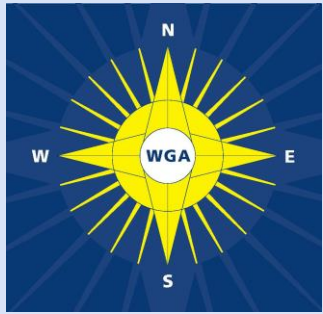
## Open Angle Glaucoma

Robert N. Weinreb and Jonathan G. Crowston

Consensus Series - 2

Association of International Glaucoma Societies

**The Global Glaucoma Network**



**Fort Lauderdale April 30, 2005**

**WGA**



**The Global Glaucoma Network**



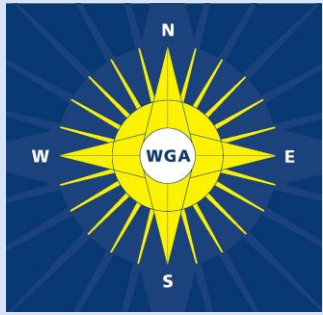
# Indications for Surgery

**WGA**

- 1. The decision for surgery should consider the risk/benefit ratio.**

**Note: Although a lower IOP is generally considered beneficial to the eye, the risk of vision loss without surgery must outweigh the risk of vision loss with surgery.**

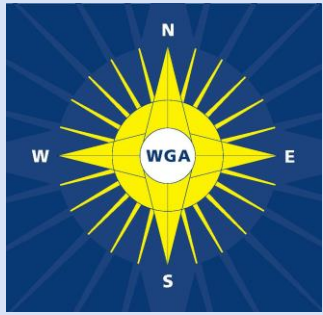




# Indications for Surgery

**WGA**

- 2. Surgery for glaucoma is indicated when:**
  - a. Optimum medical therapy and/or laser surgery fails to sufficiently lower IOP.**
  - b. A patient does not have access to or cannot comply with medical therapy.**



# Indications for Surgery

**WGA**

**3. Clinicians should generally measure IOP more than once and preferably at different times of day when establishing baseline IOP prior to surgery.**

**Note: When IOP is markedly elevated, a single determination may be sufficient.**



# Indications for Surgery

**WGA**

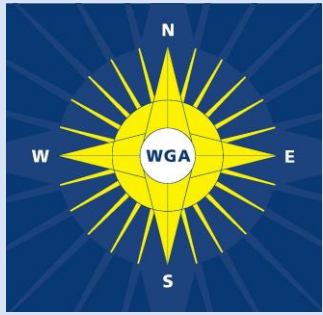
4. Progression of glaucoma, considering both the structural and functional integrity of the optic nerve, is clearly a threat to vision and strongly influences the threshold for surgery.



# Indications for Surgery

**WGA**

5. Ongoing care of the patient with glaucoma requires careful periodic evaluation of structure and function.



# Indications for Surgery

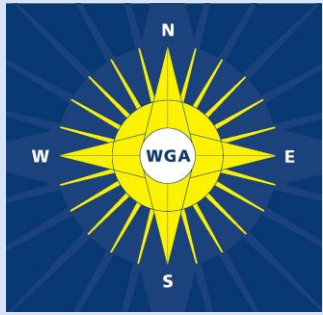
**WGA**

**6. Efforts should be directed at estimating the rate or risk of progression. A greater rate or risk of progression may lower the threshold for surgery but must be balanced against the risk and benefits of surgery and the life expectancy of the patient.**

*Comment:* An elderly patient with slow progression may suffer no effect on quality of life during his/her lifetime.

*Comment:* Advancing glaucomatous optic disc damage or retinal nerve fiber loss without detected visual loss is progression and can in certain circumstances be an indication for surgery.

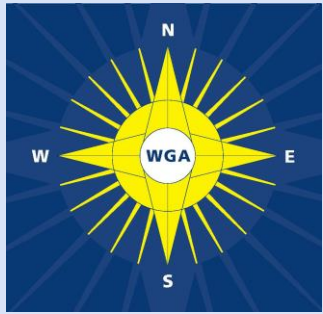




# Indications for Surgery

**WGA**

7. Risk factors for progression of glaucoma are emerging from prospective studies. [AGIS-older age, lower education, male sex, diabetes; CNTGS-female sex, migraine; EMGT- high IOP, pseudoexfoliation, worsening visual fields during follow up, disc hemorrhage, advanced stage of disease] Presence of these risk factors may alter target IOP or lower the threshold to surgery.



# Indications for Surgery

**WGA**

**8. Fellow eye vision loss from glaucoma may lower the threshold IOP for consideration of surgery. It is not clear that it is a risk factor for threat to vision.**

***Comment:*** Family history of blindness from glaucoma is not a known risk factor for vision loss, but such patients warrant close observation.



# Indications for Surgery

**WGA**

**9. Primary surgery may be indicated on the basis of socioeconomic or logistic constraints.**

***Comment:* There is insufficient evidence to recommend primary surgery in all patients.**

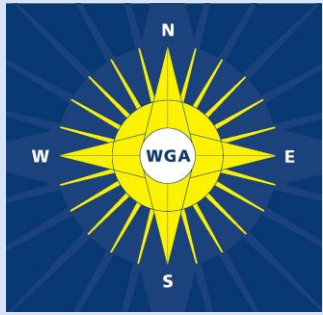


# Indications for Surgery

**WGA**

**10. Patients who are unable or unwilling to use their medical therapy as prescribed represent failures of treatment efficacy and may need surgery to achieve consistent IOP reduction, even when isolated IOP measurements appears normal at office visits.**

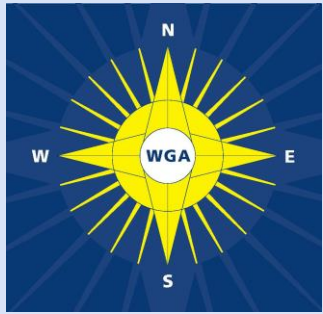




# Indications for Surgery

**WGA**

**11. The extent and location of damage may alter the threshold for surgery. Patients with advanced damage or damage threatening central vision may require lower IOP than those with early disease.**



# Laser Trabeculoplasty

**WGA**

1. Laser trabeculoplasty (LTP) with diode, or frequency doubled Q-switched Nd:YAG are effective methods to lower IOP.
2. The principal indication for laser trabeculoplasty remains the failure of medical therapy to sustain acceptable IOP levels in adult eyes with POAG or intolerance of medical therapy. However, in appropriate cases LTP may be used as a primary therapy.



# Laser Trabeculoplasty

3. Although IOP lowering after LTP tends to wane with time, it may produce clinically significant IOP reduction in phakic eyes for up to several years

*Comment:* LTP often is effective in pseudophakic eyes for up to several years.

4. Postoperative monitoring of IOP and follow up treatment of intraocular pressure spikes is appropriate.

*Comment:* IOP spikes tend to occur within the first few postoperative hours.

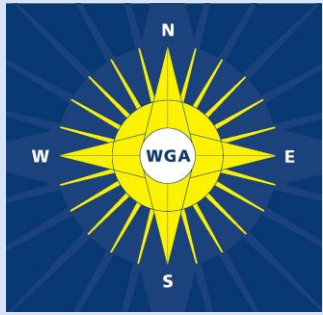


# Laser Trabeculoplasty

**WGA**

5. Uveitis, ICE syndrome, congenital anomalies of the anterior chamber angle, and poor visualization of angle structures are contraindications for LTP, while age < 40 year, angle recession, traumatic glaucoma and high myopia are relative contraindications.
6. All commonly employed methods of LTP appear to be equivalent with respect to short-term side effects and IOP lowering.

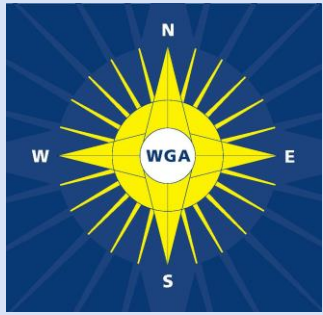




# Laser Trabeculoplasty

**WGA**

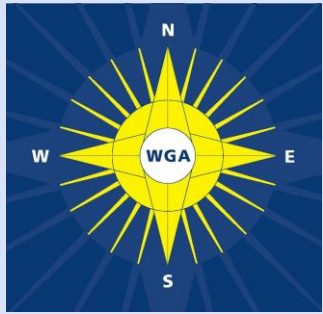
7. There is longer follow-up data available for argon laser trabeculoplasty (ALT) than for selective laser trabeculoplasty (SLT). Randomized studies comparing these two modalities are not yet available.
8. Retreatment with ALT (applying additional laser spots to areas of the meshwork previously treated) is likely to be ineffective and perhaps detrimental. Although retreatment with SLT has a theoretical advantage, studies to prove this have not yet been reported



# Wound Healing

## WGA

1. Excessive healing at the conjunctiva-Tenon's fascia-episcleral interface is the major cause of inadequate long term IOP lowering after trabeculectomy.
2. Risk factors for scarring should be evaluated and documented in all patients prior to undergoing glaucoma filtration surgery (see appendix).  
*Comment:* Conjunctival inflammation should be minimized prior to surgery.



# Wound Healing

**3. The use of adjunctive antifibrosis agents should be considered in most patients undergoing trabeculectomy and should be titrated against the estimated risk of postoperative scar formation and estimated risk for postoperative complications.**

***Comment:*** Although some patients may have a successful result without adjunctive antifibrosis use, there is no systematic method for identifying these patients.

***Comment:*** Different antifibrotic agents may be associated with different risks and benefits. MMC may be a more effective adjunct than 5-FU but is associated greater complications.

***See next slide for more comments***



# Wound Healing

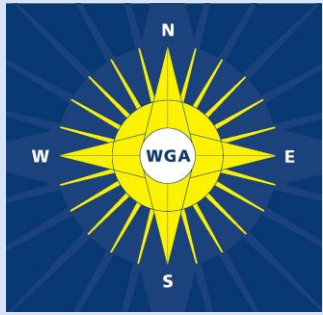
WGA

*Additional comments to statement 3 on previous slide*

**Comment:** A large antifibrotic treatment area is desirable to achieve diffuse non-cystic blebs with a lower risk of discomfort and leakage.

**Comment:** Complications related to the use of antifibrosis agents are usually related to excessive inhibition of wound healing, which may result in or prolong early (wound leak, hypotony, shallow anterior chamber, choroidal detachment, etc) and late (hypotony maculopathy, wound leak, and bleb-related ocular infection, etc,) complications.



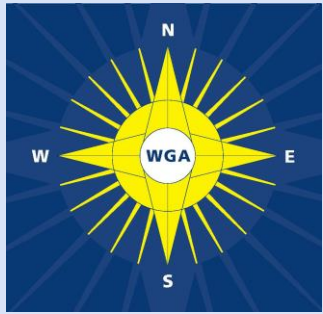


# Wound Healing

**WGA**

**4. Modern trabeculectomy techniques that include the use of lasered/releasable/adjustable sutures should be employed to minimize the complications of excessive filtration.**

***Comment to this statement on next slide***



# Wound Healing

**WGA**

**5. Early intervention (subconjunctival 5-FU and increased topical steroids) is recommended in eyes with evidence of active scar formation (conjunctival hyperemia and anterior chamber inflammation)**

***Comment:*** Use of subconjunctival 5-FU in eyes with a wound leak, corneal defect or ocular hypotony should be cautioned.

***Comment:*** Postoperative IOP elevation typically occurs after significant scarring has already taken place. As the scarring process might be slowed with additional measures, but not likely reversed, it is advised to intervene prior to an actual IOP rise, based on signs indicating the likelihood of an active scarring process.

***Comment also belongs to statement 4 on previous slide***



# Wound Healing

WGA

6. Antifibrosis use is associated with enhanced bleb formation and lower intraocular pressure. However, they also have an increased long-term risk.

*Comment:* It is essential to inform patients about the signs and symptoms of ocular infection and advise them that they should seek ophthalmological advice urgently, should they occur. Long term follow up of these eyes is advisable.

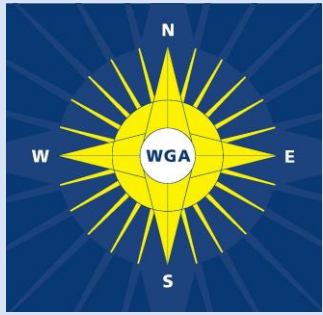


# Trabeculectomy

**WGA**

- 1. Incisional surgery for glaucoma is indicated when medical therapy and/or laser fail to sufficiently lower IOP or the patient does not have access to, or cannot comply with, other forms of therapy.**

***Comment:*** Primary surgery may also be indicated on the basis of socioeconomic or logistical constraints.

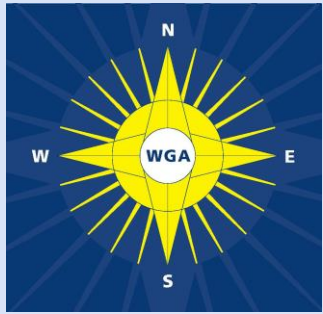


# Trabeculectomy

**WGA**

2. Trabeculectomy is the incisional procedure of choice in previously unoperated eyes.
3. Postoperative hypotony should be avoided and sequential IOP adjustment should be performed with suture modification.
4. Trabeculectomy provides better and more sustained IOP lowering than nonpenetrating procedures.

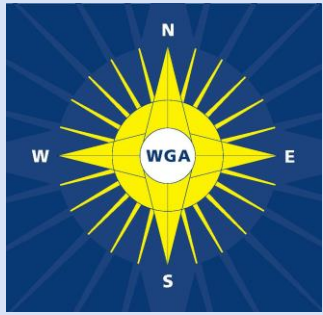




# Trabeculectomy

**WGA**

- 5. Although adjunctive antifibrosis agents enhance the success of trabeculectomy, their risk/benefit ratio should be assessed for each individual patient prior to use. This applies to initial and repeat surgeries.**
- 6. Preoperative conjunctival inflammation and postoperative conjunctival and intraocular inflammation should be suppressed vigorously with glucocorticoids.**



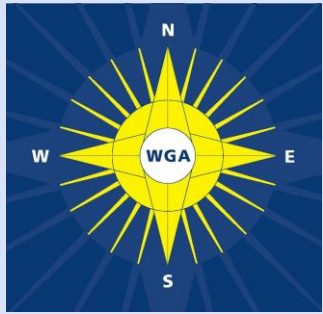
# Trabeculectomy

**WGA**

**7. Trabeculectomy success is highly dependent on postoperative care and management.**

***Comment:* Early recognition of postoperative complications and timely, appropriate intervention enhances the success rate of surgery and minimizes patient morbidity.**

**8. Patients that have had trabeculectomy should be warned of the signs and symptoms of late bleb-related ocular infection and should be counseled to seek immediate attention should these occur.**



# Combined Cataract / Trabeculectomy

1. A combined procedure is usually indicated when surgery for intraocular pressure (IOP) lowering is appropriate and a visually significant cataract is also present.

*Comment:* Patients with glaucoma who are undergoing cataract do not necessarily require combined surgery. To avoid the complications associated with increased postoperative IOP, however, combined procedures should be considered in those patients on multiple medications or with advanced glaucomatous optic neuropathy.

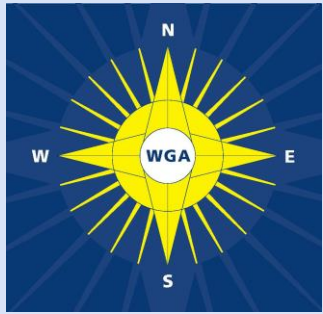


# Combined Cataract / Trabeculectomy

2. The indication for combined surgery in an individual patient should take into account the level of desired IOP control after surgery, the severity of glaucoma and the anticipated benefit in quality of vision after cataract extraction.

*Comment:* Visual rehabilitation may take longer following combined surgery compared to cataract surgery alone.

3. There is limited evidence to differentiate a one-site vs. a two-site approach for combined surgery. Therefore, surgeon preference and experience will dictate the choice.

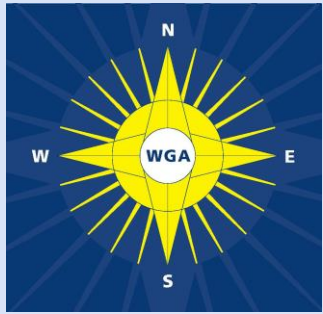


# Combined Cataract / Trabeculectomy

4. There is limited evidence to differentiate a limbal vs. a fornix-based conjunctival incision for combined surgery. Therefore, surgeon preference and experience will dictate the choice.
5. Mitomycin-C should be considered in all combined procedures to improve the chance of successful IOP control, unless there is a clear contraindication for its use.

*Comment:* Evidence for the use of adjunctive 5-fluorouracil data is limited and the bulk of the evidence suggests that it does not work well or at all.



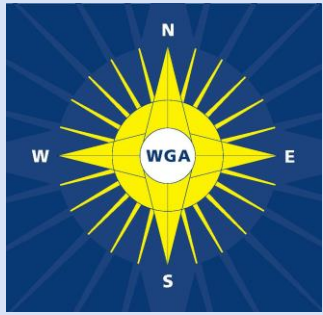


# Combined Cataract / Trabeculectomy

**6. Combined procedures are less successful for IOP reduction than trabeculectomy alone.**

*Comment:* subsequent cataract surgery may compromise the success of earlier trabeculectomy surgery.

**7. In patients with cataract and stable glaucoma, a clear corneal approach is preferable in patients who may require subsequent trabeculectomy.**



# Aqueous Shunting Procedures with Glaucoma Drainage Devices

- 1. Glaucoma drainage devices are indicated when trabeculectomy is unlikely to be successful or because of socioeconomic or logistical issues.**

*Comment:* In some patients, GDDs should be considered for socioeconomic or logistic issues relating to safety, follow up care, etc.



# Aqueous Shunting Procedures with Glaucoma Drainage Devices

1. The restriction of flow of aqueous humor from the eye is important in the prevention of immediate postoperative hypotony.

*Comment:* GDDs that do not have mechanisms to restrict aqueous flow require a suture ligature or internal stent or other flow restricting mechanism.

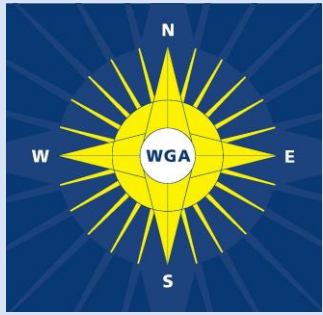


# Aqueous Shunting Procedures with Glaucoma Drainage Devices

3. In general, larger surface areas of the plate are associated with lower IOP.

4. Scar formation around the plate is the main cause of long-term device failure.

*Comment:* Antifibrotic agents have not been shown to improve long-term success when used intraoperatively or postoperatively.

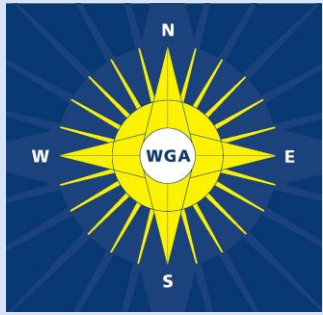


# Aqueous Shunting Procedures with Glaucoma Drainage Devices

5. Pars plana positioning of a GDD should be considered in a patient with a prior pars plana vitrectomy or in patient in whom a tube cannot be safely inserted into the anterior chamber
6. The preponderance of evidence addresses GDDs that drain to a posterior reservoir.

*Comment:* Anterior drainage devices are under study. One should not extrapolate data from posterior drainage to anterior drainage devices.



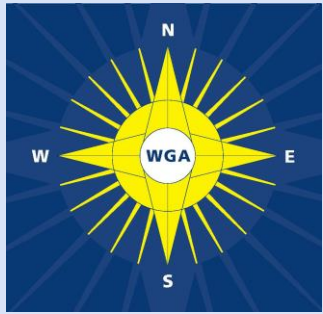


# Comparison of Trabeculectomy vs. Aqueous Shunting Procedures with Glaucoma Drainage Devices

1. Trabeculectomy with MMC is less expensive and requires less conjunctival dissection than aqueous shunting procedures.

*Comment:* Cost of GDDs vary significantly throughout the world.

2. With increased conjunctival scarring, the success of MMC trabeculectomy is reduced. Aqueous shunting procedures should be considered in patients with failed MMC trabeculectomy.



# Comparison of Trabeculectomy vs. Aqueous Shunting Procedures with Glaucoma Drainage Devices

3. In general, lower IOP can be achieved with MMC trabeculectomy compared with aqueous shunting procedures, but good clinical studies are lacking.

*Comment:* There are currently limited data from prospective randomized comparisons between MMC trabeculectomy and aqueous shunting procedures. To adequately compare MMC trabeculectomy with aqueous shunting procedures, comparable patient populations are required.



# Comparison of Trabeculectomy vs. Aqueous Shunting Procedures with Glaucoma Drainage Devices

4. Bleb related complications are less prevalent after aqueous shunting procedures. However, aqueous shunting procedures introduce a distinct set of complications including tube erosion or plate erosion, endothelial decompensation and strabismus.
5. Aqueous shunting procedures (ASPs) should be considered in patients at high risk of MMC-related postoperative complications. These include severe lid margin disease, chronic contact lens wear, and a history of blebitis or bleb-related endophthalmitis.



# Non Penetrating Glaucoma Drainage Surgery (NPGDS)

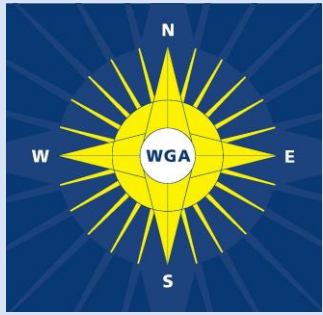
WGA

1. NPGDS provides an alternative surgical approach to trabeculectomy for moderate lowering of IOP in glaucoma patients.

2. Post-operative Nd:YAG laser goniopuncture may be an integral part of the procedure.

*Comment:* Laser goniopuncture is akin to flap suture manipulations following trabeculectomy.

3. Unlike viscocanalostomy, external filtration with deep sclerectomy may enhance the success of the procedure.

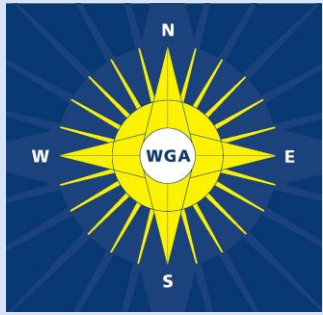


# Non Penetrating Glaucoma Drainage Surgery (NPGDS)

**WGA**

4. Deep sclerectomy may provide a lower IOP than viscocanalostomy, although the evidence for this is limited.
5. Failed NPGDS may compromise the success of subsequent trabeculectomy.

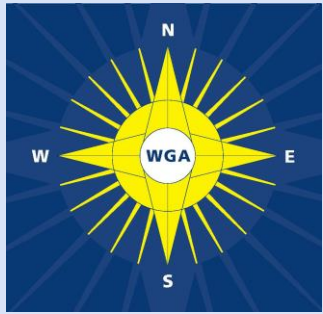




# Comparison of Trabeculectomy vs. Non Penetrating Glaucoma Drainage Surgery (NPGDS)

1. Lower IOP can be achieved with trabeculectomy than with NPGDS
2. Short-term complications associated with NPGDS may be fewer and less severe
3. NPGDS is technically more challenging, with a longer operative time.

*Comment:* Both procedures may require postoperative intervention.



# Cyclodestructive Procedures

WGA

1. Of the cyclodestructive procedures, laser diode cyclophotocoagulation, with the G-probe, is the procedure of choice for refractory glaucoma when trabeculectomy and drainage implants have a high probability for failure or have high risk of surgical complications.
2. Transscleral cyclophotocoagulation may be considered when maximal medical therapy, trabeculectomy or drainage implant surgery is not possible due to resource limitations.



# Cyclodestructive Procedures

3. Prior to transscleral cyclophotocoagulation treatment, transillumination of the globe to reveal the location of the ciliary body may be useful, especially in morphologically abnormal eyes.
4. Post-operative treatment consisting of topical steroids and cycloplegics is suggested to minimize post-operative complications and discomfort.

*Comment:* The effectiveness of treatment should be assessed after 3-4 weeks, at which time re-treatment may be considered.

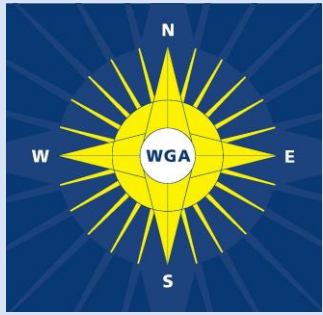
*Comment:* less intense laser therapy on a repeated basis rather than a single high dose treatment is suggested to minimize complications of treatment.



# Comparison of Cyclophotocoagulation and Glaucoma Drainage Device

**WGA**

- 1. Mechanism of action**
  - a) Glaucoma drainage Devices (GDD) increase aqueous humor outflow**
  - b) Cyclodestructive procedures reduce aqueous production**
- 2. GDD implantation requires greater surgical training and is a more extensive procedure than cyclodestruction.**
- 3. GDD implantation requires greater postoperative care than cyclodestruction**

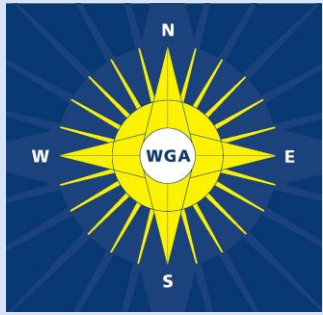


# Comparison of Cyclophotocoagulation and Glaucoma Drainage Device

**WGA**

- 4. GDD implantation should be performed in an operating room while cyclodestruction can be performed in the office, minor surgery area or in the operating room.**





# Comparison of Cyclophotocoagulation and Glaucoma Drainage Device

**WGA**

5. The marginal cost of GDD implantation is more expensive than cyclodestruction. The initial cost of cyclodestruction related to the purchase of the device used for the procedure may be greater than that with GDD implantation.
6. Preoperative visual acuity may impact which of these two treatment modalities are preferred. All other things being equal, GDD are more commonly used for patients with better visual acuity and/or visual potential relative to cyclodestructive procedures. Strong evidence in support of this practice is not currently available.